



# Significance of crown shape in the replacement of a central incisor with a single implant-supported crown

Luca Gobbato, DDS<sup>1</sup>/Gianluca Paniz, DDS<sup>2</sup>/Fabio Mazzocco, DDS<sup>3</sup>/  
 Andrea Chierico, DDS<sup>4</sup>/Teppei Tsukiyama, DDS<sup>5</sup>/Paul A. Levi Jr, DMD<sup>6</sup>/  
 Arnold S. Weisgold, DDS<sup>7</sup>

**Objective:** When utilizing a single implant-supported crown to replace a central incisor, understanding the final shape of the implant restoration is an important factor to help achieve a successful esthetic outcome. In today's dentistry, tooth shape is a critical factor when dental implant prostheses are considered in the esthetic zone. The major esthetic goal for this type of restoration is to achieve the closest possible symmetry with the adjacent tooth, both at the soft and at the hard tissue levels. The goal of this study was to objectively analyze the significance of natural crown shape when replacing a central incisor with a single implant-supported crown. **Method and Materials:** In this study, we investigated the shape of the crowns of maxillary central incisors in 60 individuals who presented to our clinics with an untreatable central incisor. The presence of a dental diastema, "black triangle," presence or absence of gingival symmetry, and the presence or absence of dental symmetry were recorded in the pre- and postoperative photographs.

**Results:** Out of 60 patients, 33.3% had triangular-shaped crowns, 16.6% square/tapered, and 50% square-shaped crown form. After treatment was rendered, 65% of the triangular group, 40% of the square/tapered group, and 13.3% of the square group required an additional restoration on the adjacent central incisor in order to fulfill the esthetic needs of the patients. **Conclusion:** Data analysis revealed that if there is a "black triangle," a diastema, or presence of dental or gingival asymmetry, an additional restoration on the adjacent central incisor is often required in order to fulfill esthetic goals. The additional restoration is highly recommended in situations with a triangular crown shape, while it is suggested in cases of square/tapered and square tooth shapes in the presence of a dental diastema. (doi: 10.3290/j.qi.a29146)

**Key words:** *biotype, black triangle, dental implant, esthetics, interproximal papilla, tooth shape*

<sup>1</sup>Clinical Instructor, Department of Oral Medicine, Infection & Immunity, Harvard School of Dental Medicine, Boston, MA, USA.

<sup>2</sup>Adjunct Assistant Professor, Department of Prosthodontics and Operative Dentistry, Tufts University School of Dental Medicine, Boston, MA, USA.

<sup>3</sup>Private Practice, Padova, Italy.

<sup>4</sup>Private Practice, San Pietro in Cariano, Verona, Italy.

<sup>5</sup>Private Practice, Japan.

<sup>6</sup>Clinical Associate Professor, Department of Periodontology, Tufts University School of Dental Medicine, Boston, MA, USA.

<sup>7</sup>Adjunct Professor, Department of Periodontics, University of Pennsylvania School of Dental Medicine, Pennsylvania, PA, USA.

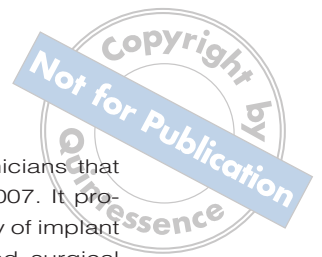**Correspondence:** Dr Luca Gobbato, Harvard School of Dental Medicine, Department of Oral Medicine, Infection & Immunity, 190 Longwood Avenue, Boston, MA 02115. Email: Luca\_Gobbato@hsdm.harvard.edu

Since implant dentistry has become a common treatment for replacing missing teeth, dentists have been trying to mimic natural tooth morphology in order to achieve a proper functional result and to fulfill the patient's esthetic desires.<sup>1-3</sup>

The criteria for implant success<sup>4,5</sup> published in 1986 have since been profoundly reviewed, and what was considered the standard of care 20 years ago is not necessarily valid today. The criteria then for an implant included osseointegration and the possibility for an optimal restoration.

Today achieving an acceptable treatment outcome in implant dentistry no longer depends on simply achieving osseointegration or being able to restore an implant.<sup>6</sup>





Clinical success now demands that, at the least, an esthetically pleasing result as determined by the patient and the clinician should be the therapeutic end point. This means establishing an ideal balance between the "pink" and the "white" component of the dentogingival complex, as discussed by Buser and coworkers when defining the white esthetic score (WES) and the pink esthetic score (PES).<sup>7</sup>

Esthetic dentistry involves both psychoanalytic and social behaviors. The treatment of someone's smile is a delicate and extremely important result of treatment, not only because the smile is one of the first things people see, but also because an attractive smile improves overall appearance and helps provide an individual with self-confidence.

In an ideal situation, the operator should follow documented prosthetic guidelines in order to achieve the optimal esthetic goals including: symmetry, harmony, unity with variety, and an appropriate tooth shade.<sup>2,8</sup> Compromising one of these factors will ultimately result in an unfavorable result especially when dealing with the maxillary central incisors.<sup>9</sup>

Despite the biological and technical advances recently made in the field of implant dentistry, there are still a number of clinical scenarios where clinicians may encounter certain limitations in their ability to achieve the ideal esthetic outcome. The widespread use of dental implants as the therapy of choice to replace missing teeth means that clinicians involved in patient care must foresee these limitations and understand the final outcome of the treatment as much as possible before therapy begins. Addressing the specific risk indicators during the diagnostic phase will help therapists identify when additional therapy may be required or when an outcome that may not match dentist or patient expectations is likely to occur.

To help categorize the difficulty level of a given treatment, in 2007 the International Team for Implantology (ITI) formalized a system of classification for dental implant procedures to support clinicians at every level of expertise and experience.<sup>10</sup> This publication is based on the debate and findings of an ITI Consensus Conference attended by a

multidisciplinary group of 28 clinicians that was held in Mallorca in March 2007. It provides guidelines to a broad variety of implant situations for both restorative and surgical cases, which are classified according to three categories: straightforward (S), advanced (A), and complex (C) (SAC). Acknowledging the challenging clinical conditions often present in the anterior maxilla such as lip line at smile, number of missing teeth, bone quality and quantity, gingival biotype, and the tooth shape can profoundly influence the degree of treatment risk.<sup>10</sup>

When utilizing a single implant-supported crown to replace a central incisor, understanding the final shape of the implant restoration is an important factor to achieve a successful esthetic outcome. Tooth shape is a critical factor when dental implant prostheses are treatment planned in the esthetic zone.<sup>9,11,12</sup> The major esthetic goal for this type of restoration is to achieve the closest possible symmetry with the adjacent tooth at the soft and at the hard tissue levels.

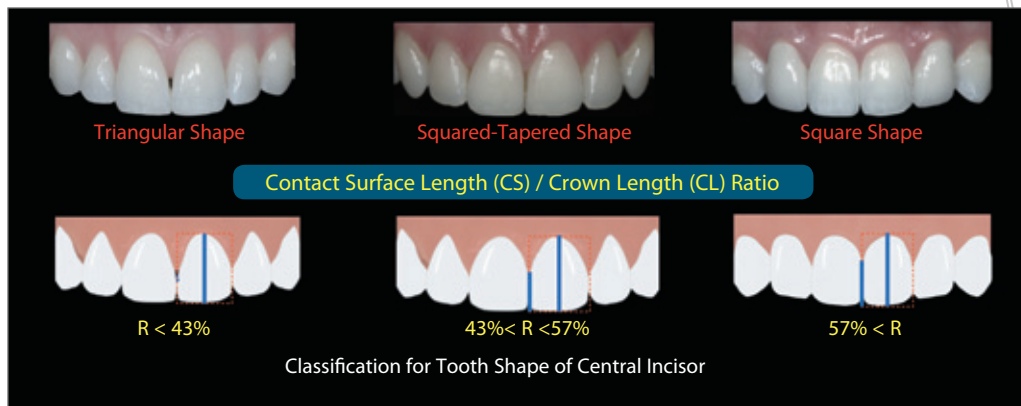
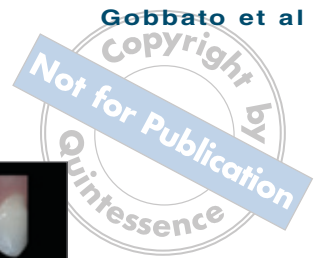The shape of the missing and adjacent teeth profoundly influence the degree of esthetic success associated with implant-supported restorations in the esthetic zone.<sup>13</sup> According to previous literature, with the esthetic outcome strongly influenced by the final gingival architecture, successful esthetic results can be enhanced by the presence of square teeth.<sup>13</sup>

In a previous study the authors identified a range of measurements in which it is possible to categorize the form of the crown of the maxillary central incisors into three different groups: triangular, square, and square/tapered.<sup>14</sup>

The purpose of this paper is to verify, through a retrospective analysis, if tooth shape can dictate decision making as to whether or not an adjacent natural central incisor will require an additional restorative procedure to enhance the final esthetic result.

## METHOD AND MATERIALS

For this retrospective analysis, consecutive patients with a central incisor treated by the authors with a single implant restoration between June 2006 and July 2011 were



**Fig 1** Classification for the tooth shape of central incisors. Regarding the CS/CL ratio (R), if CS is less than 43% of CL, the tooth is triangular in shape; if CS is more than 57% of CL, the tooth shape is square.

selected. The study population consisted of 60 adults between 22 and 37 years of age, in good health, and with growth and development completed.

As inclusion criteria, preoperative and postoperative anterior photos were required. During the recruitment of the patients the following exclusion criteria were employed: presence of a prosthetic restoration on the maxillary central incisor that was not going to be replaced, a history of tooth trauma causing a change of shape of the incisors, presence of incisal attrition, abrasion or erosion that reached the dentin, presence of crowding or tooth rotation, or evidence of altered passive eruption.

**Clinical measurements**

In the preoperative photographs the shapes of the maxillary central incisors were evaluated and each central incisor was classified as triangular, square/tapered, or square (Fig 1).<sup>14</sup>

Regarding the contact surface (CS) length/crown length (CL) ratio, if CS is less than 43% of CL, the tooth is triangular in shape; if CS is more than 57% of CL, the tooth shape is square.<sup>14</sup>

The presence of a dental diastema, “black triangle,”<sup>12</sup> presence or absence of gingival symmetry, and the presence or absence of dental symmetry was recorded by preoperative photography. The presence of a diastema was identified as a space in between the two central incisors. The pres-

ence of a “black triangle” was identified as a space that had developed when the interproximal papilla receded apically, resulting in the appearance of a dark triangle.

Gingival and dental symmetry was considered achieved when the exact correspondence of form and constituent configuration on opposite sides of a dividing center axis was present.

The same analysis was performed on the postoperative photograph (Fig 2). All patients included in the study did not have “black triangles” or diastemas at the end of treatment, and presented with gingival and dental symmetry. The initial and final condition and modifications were correlated to the treatment rendered.

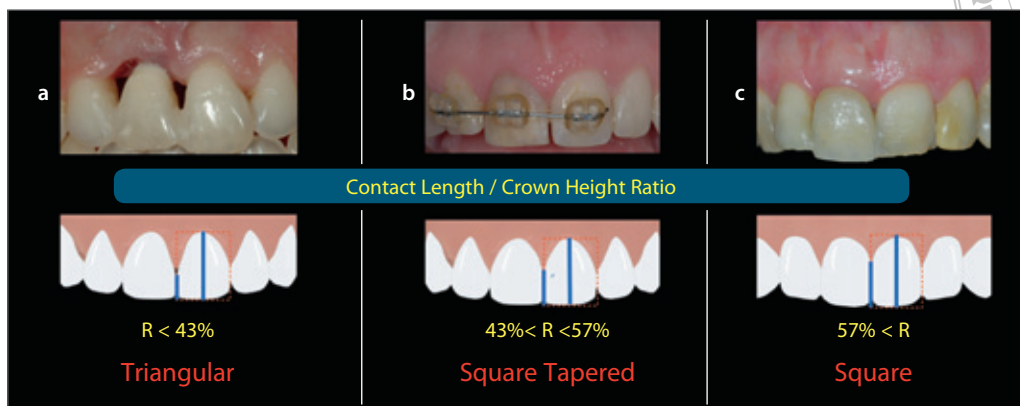
The additional restorations were subdivided into:

- additional restoration (composite resin restorations or porcelain laminate veneers; no tooth preparation was performed)
- partial or full coverage restoration (porcelain-fused-to-metal or all-ceramic restorations performed with tooth preparation).

The variables considered on the contralateral central incisor were:

- no treatment performed
- additional restoration (composite resin restorations or porcelain laminate veneers; no tooth preparation was performed)





**Fig 2** Significance of crown shape in the replacement of a central incisor with a single implant-supported crown. The diagrams represent the classification of shape:<sup>14</sup> when the CS/CL ratio is less than 43%, a maxillary central incisor is categorized as triangular; between 43% and 57%, the tooth is defined as square/tapered; more than 57%, the tooth is defined as square. (a) Anterior view of an untreatable maxillary right triangular central incisor. (b) Anterior view of an untreatable maxillary right square/tapered central incisor. (c) Anterior view of an untreatable maxillary right square central incisor.

- partial or full coverage restoration (porcelain-fused-to-metal or all-ceramic full-coverage restoration performed with tooth preparation).

**Data analysis**

A descriptive analysis was performed in order to demonstrate the correlation between the need for an additional restoration and the achievement of the esthetic result. The *P* value was set at .05.

Sixty patients were selected to be part of this retrospective analysis. We included only the cases where the esthetic outcomes were completely fulfilled (no diastema, no “black triangle,” and dental and gingival symmetry was achieved). Out of 60 patients, before the treatment was rendered 20 exhibited triangular tooth forms, 10 showed square/tapered tooth forms, and 30 had square tooth forms.

**RESULTS**

In order to achieve an acceptable esthetic result (no diastema, no “black triangle,” and dental and gingival symmetry), after implant insertion in the ideal three-dimensional position (Fig 3) 65% of the teeth that were initially triangular in shape required an additional restoration on the adjacent central

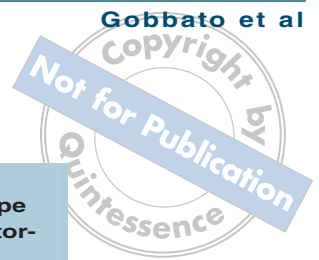incisor, 40% of the square/tapered group required an additional restoration, and only 13.3% of the square group required an additional restoration on the adjacent central incisor (Table 1, Figs 3 and 4).

Considering only the 21 patients who required an additional restoration:

- 13 subjects (61.9%) were treated with full coverage restorations with tooth preparation (all originally exhibited triangular tooth forms)
- 8 subjects (38.1%) were treated with additive composite resin restorations (4 originally exhibited square tooth shape and 4 exhibited square/tapered; Table 2).

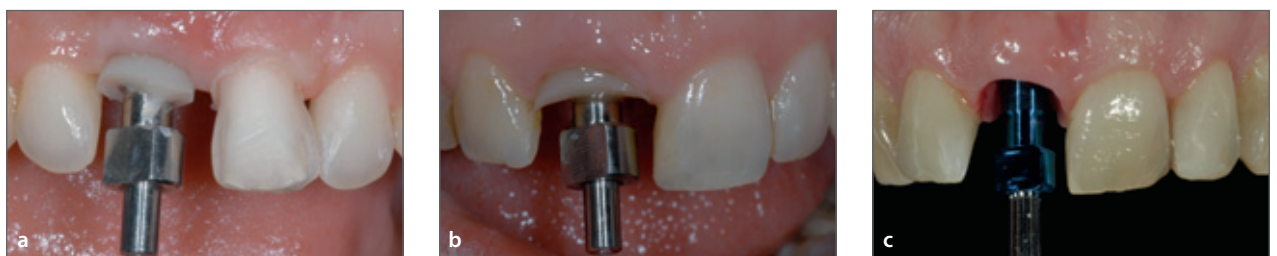As is shown in Table 3, the teeth that required an additional restoration had their original form changed from triangular or square/tapered to a square tooth shape.

A student *t* test was performed to show statistically significant differences among different groups of patients. The student *t* test was used to compare the percentage of triangular teeth that required an additional restoration with the percentage of subjects belonging to the square-shaped group that required an additional restoration (statistically significant, *P* < .05).

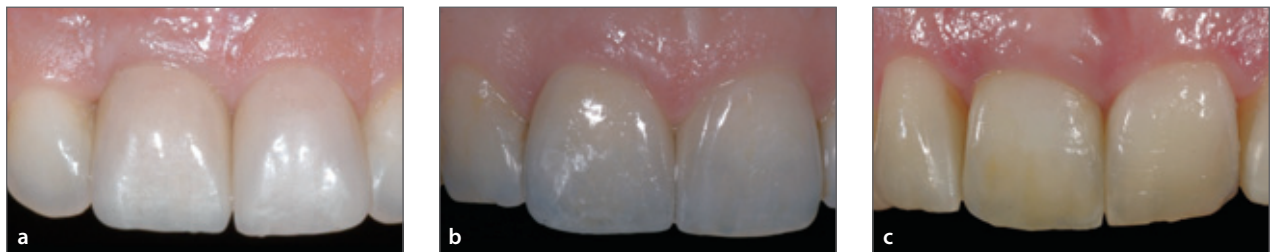

Initial shape	Requiring additional restoration	
	Yes	No
	n (%)	n (%)
Triangular	13 (65.0)	7 (35.0)
Square/tapered	4 (40.0)	6 (60.0)
Square	4 (13.3)	26 (86.7)
Total	21 (35.0)	39 (65.0)

Initial shape	Type of additional restoration	
	Crown	Additive
	n (%)	n (%)
Triangular	13 (100.0)	0 (0.0)
Square/tapered	0 (0.0)	4 (100.0)
Square	0 (0.0)	4 (100.0)
Total	13 (61.9)	8 (38.1)

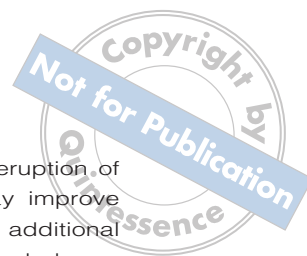

**Fig 3** (a to c) Implant placement was performed in an ideal three-dimensional position.



**Fig 4** In order to achieve acceptable esthetic results, 65% of the teeth that were initially triangular in shape required an additional restoration on the adjacent central incisor, 40% of the square/tapered group required an additional restoration, and 13.3% of the square group required an additional restoration on the adjacent central incisor. (a) Final restoration on maxillary right central incisor. A porcelain laminate veneer was added on the maxillary left central incisor in order to modify the tooth shape from triangular to square. (b) Final restoration on maxillary right central incisor. A porcelain laminate veneer with no tooth preparation was added on the maxillary left central incisor in order to close the initial diastema. (c) The final restoration on maxillary right central incisor was placed, leaving an unaltered maxillary left central incisor.

Initial shape	Final shape			
	Triangular	Square/tapered	Square	Total
	n (%)	n (%)	n (%)	n (%)
Triangular	0 (0.0)	0 (0.0)	13 (100.0)	13 (100.0)
Square/tapered	0 (0.0)	0 (0.0)	4 (100.0)	4 (100.0)
Square	0 (0.0)	0 (0.0)	4 (100.0)	4 (100.0)
Total	0 (0.0)	0 (0.0)	21 (100.0)	21 (100.0)



## DISCUSSION

The use of a single dental implant for the replacement of a maxillary central incisor is an esthetically challenging situation from both a surgical and a restorative perspective. The three-dimensional position of the fixture,<sup>9,15</sup> the gingival architecture,<sup>16,17</sup> the periodontal biotype,<sup>16-18</sup> the residual ridge dimension, and the shape and shade of the prosthesis will influence the overall appearance. The dental shape is determined by the ratio between CL and CS. Therefore a triangular-shaped tooth will have a shorter (apico-occlusal) CS when compared with a square tooth. With triangular-shaped teeth, the shorter CS is accompanied by an apico-incisally longer papilla than is seen with a square tooth. As noted by Tarnow et al,<sup>11</sup> when the vertical distance between the apical extent of the contact point and the crest of the interproximal bone is 5 mm or less the papilla is almost always present. Conversely, when the distance is 7 mm or more the papilla is usually missing. Thus, in the presence of a triangular-shaped tooth the papilla is most likely missing or at least not filling all the space required to reach the most apical portion of the CS. Within minutes following the extraction of one of the two central incisors the height of the papilla will lose vertical dimension,<sup>19</sup> creating difficulty for an esthetically satisfactory restoration. As it is not possible to predictably regenerate a papilla,<sup>20</sup> an additional restoration is required on the adjacent tooth in order to create symmetry of both central incisors, which will lengthen the contact area apico-occlusally,<sup>21</sup> shorten the apico-occlusal length of the papilla, and shorten the distance from the base of the contact point to the crest of the interproximal bone. This will help eliminate the "black triangle" caused by deficient papillary length.

If a square/tapered central incisor is being replaced by an implant, if required an adjacent additional restoration can often be performed with composite resin bonding, whereas if the central incisor is triangular, the adjacent natural tooth will most likely require a veneer or a full crown in order to achieve symmetry and provide an embrasure space filled with a papilla.

Although orthodontic driven eruption of the adjacent central incisor may improve the height of the papilla,<sup>22,23</sup> an additional restoration will most likely be needed anyway and the time of the treatment would be significantly increased.

In conclusion, there are no universal guidelines for clinicians to follow in creating greater uniformity and a predictable esthetic smile, including ideal papilla heights: the more perfect esthetics that patients demand, the more clinicians attempt to achieve perfection and ideal symmetry. Our goal is to fulfill our patient's expectations. Since esthetics is emotionally driven by each patient, the expectation and the concept of esthetics vary from patient to patient.

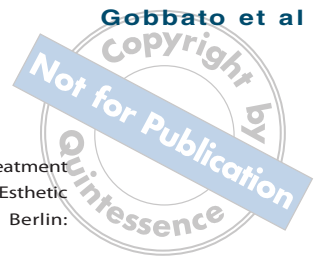## CONCLUSION

Data analysis revealed that if a "black triangle," diastema, or dental or gingival asymmetry is present, an additional restoration on the adjacent central incisor is usually required in order to fulfill the patient's esthetic goals. In the presence of a triangular tooth shape and a patient with high esthetic anticipation, a full coverage restoration may be more suitable; whereas composite resin bonding might be the suggested restoration in situations where there are square/tapered and square tooth forms in the presence of a dental diastema.

In summary, when working with a patient who requires treatment in the esthetic zone, understanding their expectations will influence treatment planning choices. Other important determinants such as tooth shape are indicators for understanding the complexity of the therapy, and will help to dictate the additional treatment that might be required in order to fulfill patient's expectations.

## REFERENCES

1. Kois JC Predictable single-tooth peri-implant esthetics: five diagnostic keys. *Compend Contin Educ Dent* 2004;25:895-896.
2. Magne P, Gallucci GO, Belser UC. Anatomic crown width/length ratios of unworn and worn maxillary teeth in white subjects. *J Prosthet Dent* 2003;89:453-461.



3. Weisgold AS, Arnoux JP, Lu J. Single-tooth anterior implant: A word of caution. Part I. *J Esthet Dent* 1997;9:225–233.
4. Albrektsson T, Jansson T, Lekholm U. Osseointegrated dental implants. *Dent Clin North Am* 1986;30:151–174.
5. Albrektsson T, Zarb G, Worthington P, Eriksson AR. The long-term efficacy of currently used dental implants: a review and proposed criteria of success. *Int J Oral Maxillofac Implants* 1986;1:11–25.
6. Cohen ES. *Atlas of cosmetic and reconstructive periodontal surgery*. Michigan: BC Decker, 2007:87.
7. Buser UC, Grütter L, Vailati F, Bornstein MM, Weber HP, Buser D. Outcome evaluation of early placed maxillary anterior single-tooth implants using objective esthetic criteria: a cross-sectional, retrospective study in 45 patients with a 2- to 4-year follow-up using pink and white esthetic scores. *J Periodontol* 2009;80:140–151.
8. Lombardi RE. The principles of visual perception and their clinical application to denture esthetics. *J Prosthet Dent* 1973;29:358–382.
9. Grunder U, Gracis S, Capelli M. Influence of the 3-D bone-to-implant relationship on esthetics. *Int J Periodontics Restorative Dent* 2005;25:113–119.
10. Dawson A, Chen S, Buser D, et al. *The SAC Classification in Implant Dentistry*. Chicago: Quintessence Publishing, 2009.
11. Tarnow DP, Magner AW, Fletcher P. The effect of the distance from the contact point to the crest of bone on the presence or absence of the interproximal dental papilla. *J Periodontol* 1992;63:995–996.
12. Buser D, Belser U, Wismeijer D (eds). *ITI Treatment Guide, Volume 1: Implant Therapy in the Esthetic Zone. Single-Tooth Replacements*. Berlin: Quintessence Publishing, 2006:159–177.
13. Buser D, Belser U, Wismeijer D (eds). *ITI Treatment Guide, Volume 1: Implant Therapy in the Esthetic Zone. Single-Tooth Replacements*. Berlin: Quintessence Publishing, 2006:15.
14. Gobbato L, Tsukiyama T, Levi Jr P, Griffin TJ, Weisgold AS. Analysis of the shapes of maxillary central incisors in a caucasian population. *Int J Periodontics Restorative Dent* 2012;32:69–78.
15. Funato A, Salama MA, Ishikawa T, Garber DA, Salama H. Timing, positioning, and sequential staging in esthetic implant therapy: a four-dimensional perspective. *Int J Periodontics Restorative Dent* 2007;27:313–323.
16. Weisgold AS, Arnoux JP, Lu J. Single-tooth anterior implant: a word of caution. Part I. *J Esthet Dent* 1997;9:225–233.
17. Kan JY, Rungcharassaeng K, Umezu K, Kois JC. Dimensions of peri-implant mucosa: an evaluation of maxillary anterior single implants in humans. *J Periodontol* 2003;74:557–562.
18. Buser D, Martin W, Belser UC. Optimizing esthetics for implant restorations in the anterior maxilla: anatomic and surgical considerations. *Int J Oral Maxillofac Implants* 2004;19(Suppl):43–61.
19. Tarnow DP, Cho SC, Wallace SS. The effect of inter-implant distance on the height of inter-implant bone crest. *J Periodontol*. 2000;71:546–549.
20. Chu SJ, Tarnow DP, Tan JH, Stappert CF. Papilla proportions in the maxillary anterior dentition. *Int J Periodontics Restorative Dent* 2009;29:385–393.
21. Stappert CF, Tarnow DP, Tan JH, Chu SJ. Proximal contact areas of the maxillary anterior dentition. *Int J Periodontics Restorative Dent* 2010;30:471–477.
22. Garber DA, Salama MA. The aesthetic smile: diagnosis and treatment. *Periodontol* 2000 1996;11:18–28.
23. Wennström JL, Lindhe J, Sinclair F, Thilander B. Some periodontal tissue reactions to orthodontic tooth movement in monkeys. *J Clin Periodontol* 1987;14:121–129.