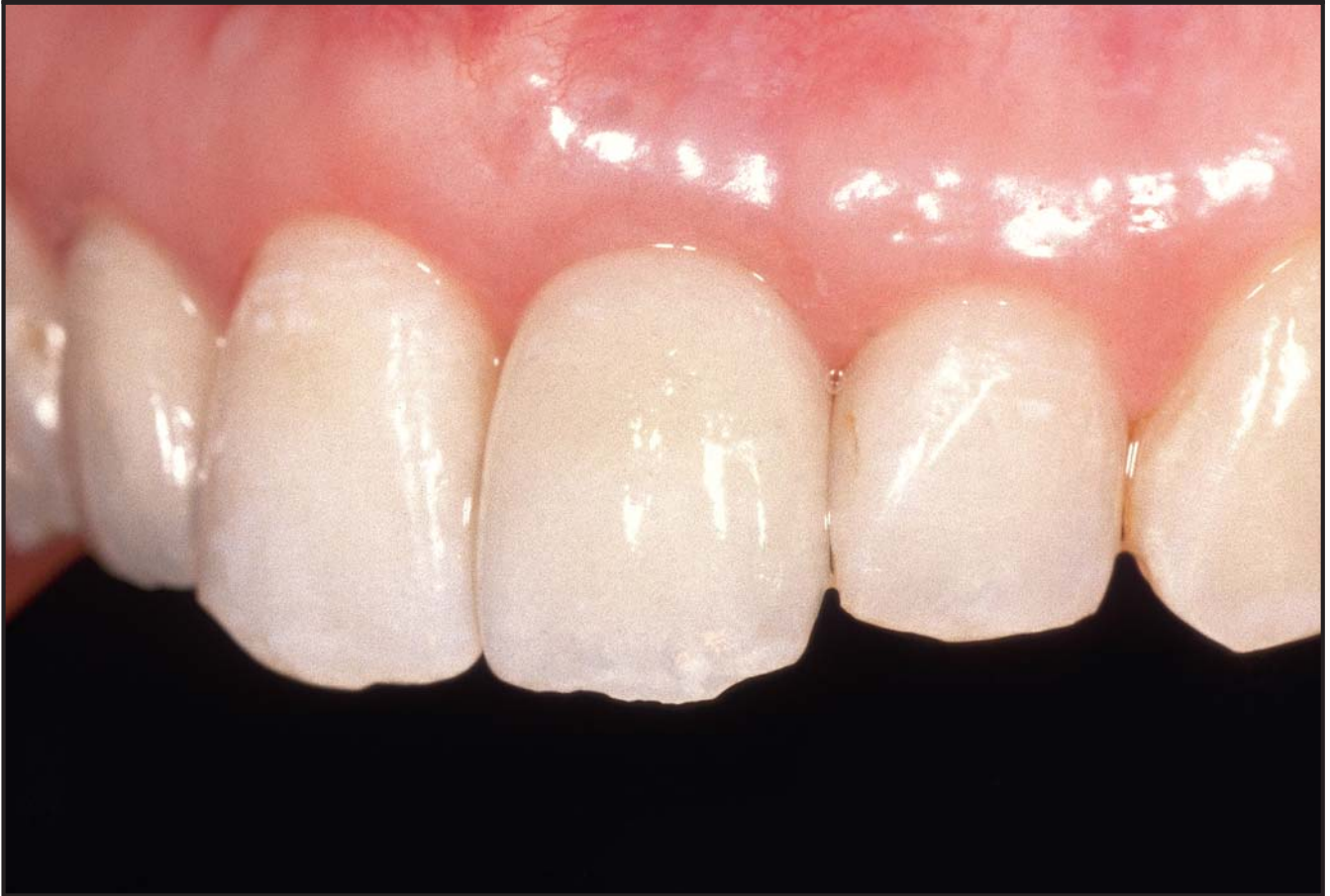
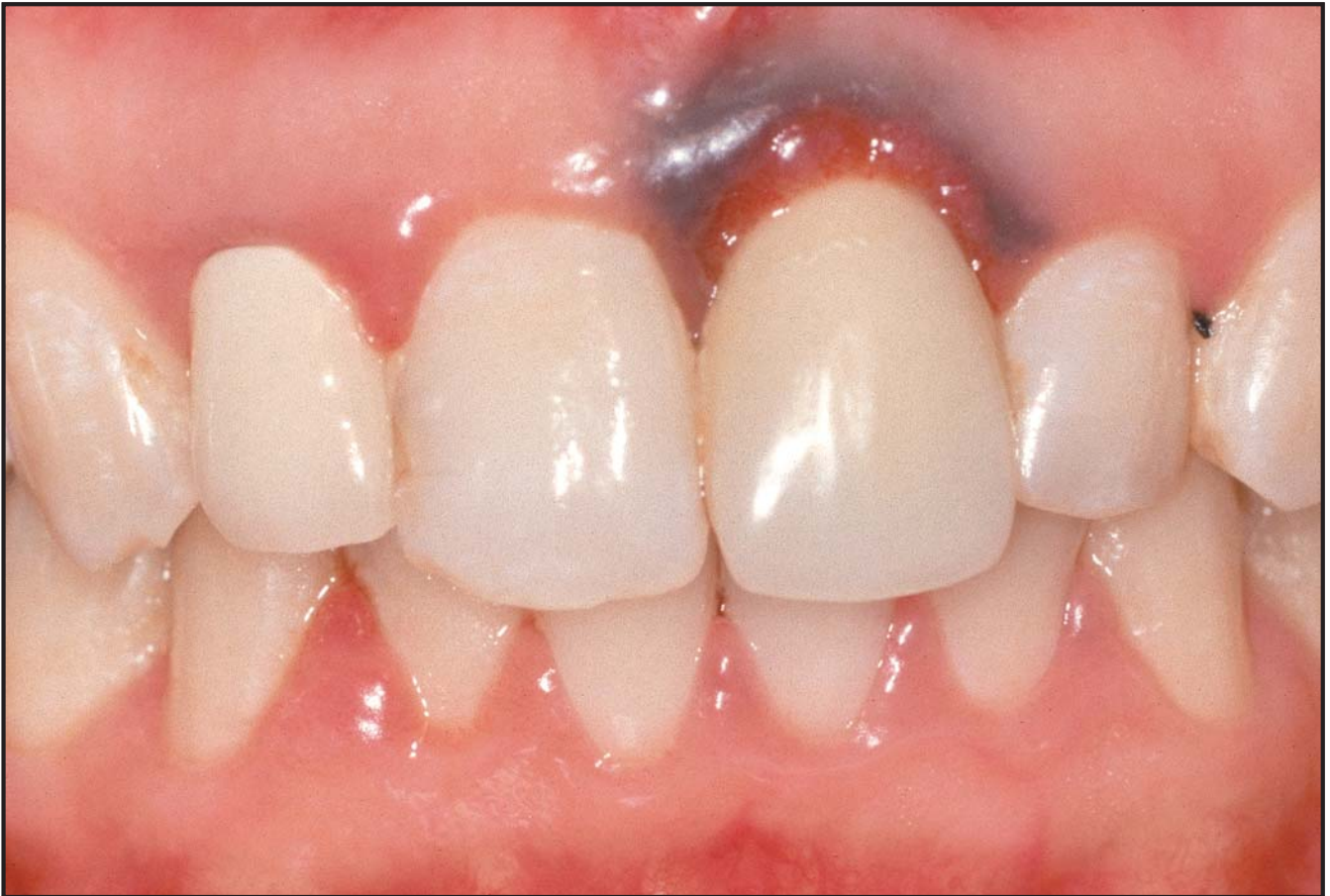
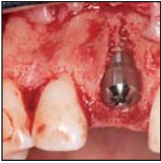

Timing, Positioning, and Sequential Staging in Esthetic Implant Therapy: A Four-Dimensional Perspective



Akiyoshi Funato, DDS*
 Maurice A. Salama, DMD**
 Tomohiro Ishikawa, DDS***
 David A. Garber, DMD**
 Henry Salama, DMD****

Many articles address the predictability of immediate implant placement into extraction sockets; however, there are only a few reports that mention the indications and limitations of this technique. The aim of this article is to re-examine specific indications for immediate implant placement and to clarify the timing or "fourth dimension" relative to extraction and implant placement. The expanded concept of four-dimensional implant treatment planning involves the new axis of time, which must be considered along with the traditional spatial or three-dimensional management of implant positioning. (Int J Periodontics Restorative Dent 2007;27:313–323.)

*Private Practice, Kanazawa, Ishikawa, Japan.

**Clinical Assistant Professor, Department of Periodontics, University of Pennsylvania, Philadelphia, Pennsylvania; Medical College of Georgia; Private Practice, Atlanta, Georgia.

***Private Practice, Hamamatsu, Shizuoka, Japan.

****Clinical Assistant Professor, Department of Periodontics, University of Pennsylvania, Pennsylvania; Private Practice, Atlanta, Georgia.

Correspondence to: Dr Maurice Salama, 600 Galleria Parkway, Suite 800, Atlanta, GA, 30339; fax: +404-261-4946.

The key to successful implant therapy in the anterior esthetic region is a harmonious relationship between the implant-supported restoration and the remaining natural teeth. The creation of a natural-looking implant restoration depends not only on the appropriate placement of an osseointegrated implant and restoration, but also on the reconstruction of a natural gingival architecture around the implant that is in harmony with the lip line and face. To achieve this goal, an implant must be conceptually planned and placed as a vertical extension of an optimally visualized restoration, as described by Garber and Belser in their concept of "restoration-driven implant treatment planning."^{1,2} This approach involves three-dimensional (3D) treatment planning, followed by placement of the implant in a position that is optimal for both function and esthetics. The initial 3D evaluation of the potential site must include planning for augmentation or preservation of the existing osseous and gingival tissues around the compromised tooth. This should be an integral part of the process, because it is known that extraction is always followed by some bone resorption, with

concomitant soft tissue recession.³⁻⁵ To achieve the optimal esthetic result, clinicians must go beyond using the most appropriate clinical techniques and armamentarium and must consider a fourth dimension: timing of the treatment sequence. This additional component in treatment planning incorporates the optimal sequential staging or timing of (1) tooth extraction, (2) preservation or enhancement of hard and soft tissue, (3) implant placement, (4) abutment connection, (5) tissue modeling with a provisional and/or a modified abutment, and (6) definitive restoration. This additional axis of time is added to the traditional 3D axes and described herein as the four-dimensional (4D) concept in implant therapy.

Successful esthetic implant therapy, then, has several sequential objectives:

1. Restoration-driven 3D implant replacement, ie, placement of the implant in the optimal position to effectively support the restoration and surrounding soft and hard tissue
2. Any necessary reconstruction of an esthetic gingival soft tissue frame incorporating the harmony or curvature to the labial free gingival margin aspect of the restoration with the definitive vertical and buccolingual presence of adjacent interdental papillae
3. A provisional restoration to maintain or modify the degree of curvature of the labial free gingival margin and provide the necessary lateral support for the interproximal papillae
4. Placement of a definitive restoration that is in harmony with the

adjacent natural teeth and surrounding soft tissue, with identical gingival color

The actual timing of tooth extraction, implant placement, and abutment connection will ultimately influence the specific outcome by limiting the number of individual auxiliary procedures while enhancing predictability. Conceptually, then, it reduces the potential number of surgical/restorative interventions, shortening the treatment span and thereby enhancing esthetic predictability. Immediate implant placement has been well documented in the literature, and the data indicate similar predictability versus the staged approach.⁶⁻¹¹ Ongoing improvements in resorbable membranes have helped expand the potential indications for immediate implant placement with decreased complications during guided bone regeneration (GBR).

Today, there is still a dichotomy of thought regarding the timing of extraction and implant placement, and it is the authors' contention that no single method is a panacea; rather, there are specific clinical indications for each. The aim of this article is to re-examine specific indications for immediate implant placement and to clarify the timing or fourth dimension relative to extraction and implant placement. The expanded new concept of 4D implant treatment planning involves time, which must be included with the traditional spatial or 3D management of implant positioning.

The timing of tooth extraction and implant placement is classified as follows:

- Class 1: Extraction, with immediate implant placement directly into the alveolar socket via (a) "incisionless" implant placement or (b) the raising of a mucoperiosteal flap and placement of the implant into the extraction socket concomitant with either (i) osseous augmentation or GBR or (ii) a connective tissue or allograft.
- Class 2: Early implant placement. The implant is placed after extraction, and soft tissues are allowed to heal for 6 to 8 weeks. GBR can be performed at the time of extraction and/or at the time of implant placement.
- Class 3: Delayed implant placement. The implant is placed a minimum of 4 to 6 months after extraction, with preservation of the alveolar ridge using grafting techniques and/or GBR, either at the time of extraction or concomitant with implant placement. Soft tissue reconstruction in these cases will invariably be required.

Based on this classification, a tooth targeted for immediate implant placement should be diagnosed as nonsalvageable for the following reasons: (1) endodontic failure, (2) internal and/or root resorption, (3) subcrestal extensive caries, or (4) root fracture. Conceptually, the targeted tooth demonstrates no osseous compromise; clinically, the bone on the immediately adjacent teeth should be evaluated as to the relative height of the interproximal height of bone (IHB),^{12,13} since it is this IHB on the adjacent tooth that effectively determines the absence or presence of a natural papilla.

It has been determined that a distance of 4.5 mm from the desired contact point, or from the tip of a papilla to the peak of the interproximal height of bone on the teeth adjacent to the implant site, is the mean dimension for the predictable presence of a "full" papilla.¹² Immediate implant placement into these types of extraction sockets with four walls shows better esthetic predictability than the replacement of teeth with periodontal compromise. If the targeted tooth or any adjacent tooth shows an IHB with a distance in excess of 4.5 mm, then delayed placement is preferable, with preemptive orthodontic treatment of the tooth to be extracted or subsequent orthodontic treatment of the adjacent teeth to ensure esthetic predictability. In many cases, orthodontic eruption, as a preliminary step to extraction with immediate implant placement, even in a type 1 site, provides the clinician the esthetic and mechanical advantages of added osseous support to compensate for the bone loss inevitable with extraction. This is particularly necessary in Asian patients, who often have extremely thin labial plates of bone in the maxillary anterior region. In these thin scalloped biotypes, even though a thin labial alveolar bone is present following implant placement, 1 to 3 mm of gingival recession invariably occurs over time following the connection of the abutment because of remodeling of the hard and soft tissues around implants.¹⁴⁻¹⁶

Orthodontic extrusion

Salama and Salama¹⁷ reported on the advantages of orthodontic eruption as a preliminary step to implant placement. These include the following:

1. It decreases or minimizes the "gap" between the implant body and the extraction socket by coronally relocating a narrower portion of the root for extraction and therefore resulting in a smaller-diameter socket.
2. It helps enhance primary stability in the alveolus by developing the alveolar bone beyond the root apex.
3. It augments the crestal alveolar bone and overlying gingival tissues, decreasing the negative impact of postoperative alveolar resorption and gingival recession.
4. By loosening the tooth, it helps facilitate extraction.
5. It increases the mitotic turnover of the cells in the region, enhancing the potential for more rapid healing.

Orthodontic eruption should be used to generate at least 2 mm of additional vertical gingival tissue as compared to the adjacent teeth to provide for a harmonious gingival arrangement. After a 12-week period of retention, the alveolar osseous crest on the facial and interproximal aspects is confirmed by bone sounding. In addition, a computerized tomographic scan can be performed to evaluate whether there is sufficient bone available to facilitate extraction with immediate implant placement without resultant esthetic compromise.

Potential or future extraction sites are now routinely augmented vertically by orthodontics from a class 2 to a class 1 site (based on the classification system described in next section) when needed.

Classification of immediate implant placement sites

The classification detailed below and in Table 1 is based on both the osseous and soft tissue levels of the potential site at the time of extraction.

- Class 1: The buccal bone is intact, with a thick gingival biotype. "Incisionless" implant placement without flap reflection is viable (Fig 1).
- Class 2: The buccal bone is intact with a thin, more scalloped gingival biotype. Incisionless implant placement is viable, but in combination with a connective tissue graft or a subsequent secondary connective tissue graft (staged) (Fig 2).
- Class 3: The buccal bone is lost, but the implant can still be placed immediately within the remaining alveolar housing of the extraction socket, with the necessary osseous support provided through regeneration using a membrane with GBR and incorporating a simultaneous connective tissue graft. Depending on the degree of compromise to the buccal plate, the case may alternatively be handled in a staged approach using a socket augmentation procedure and subsequent implant placement. In many instances, especially

Table 1 Classification of immediate implant placement				
Class	Buccal bone	Viable implant placement technique	Expected results of immediate implant placement	Indication for immediate implant placement
Class 1	Intact with thick gingival biotype	Immediate without flap reflection	Optimal	Yes
Class 2	Intact with thin gingival biotype	Immediate with CTG or staged CTG	Good	Yes
Class 3	Deficient but implant placement possible in remaining alveolar housing of extraction socket	Simultaneous immediate with GBR and CTG or followed by staged CTG	Acceptable	Limited
Class 4	Deficient and implant may deviate from alveolar housing	Delayed	Unacceptable	No

CTG = connective tissue graft.

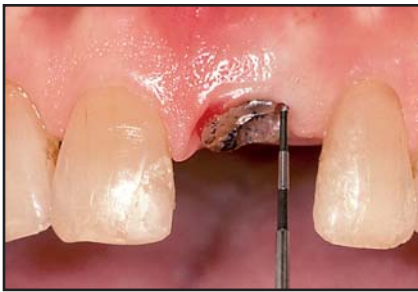

Fig 1a (left) This case is categorized as class 1. Following orthodontic extrusion, the maxillary left central incisor was extracted. The existing buccal bone was confirmed by bone sounding with a periodontal probe. A thick biotype was diagnosed.

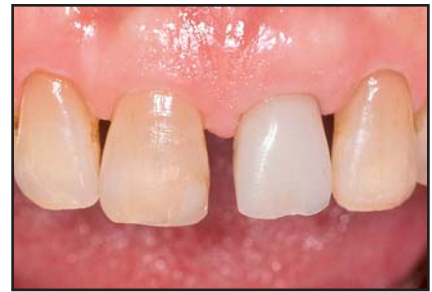

Fig 1b (right) An implant was placed "incisionless" without flap reflection, and a provisional restoration was placed immediately.

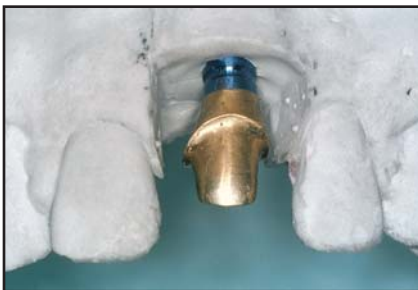

Fig 1c (left) Facial view of the definitive implant analog and definitive abutment. An abutment access hole cannot be seen, confirming that the extended long axis of the implant would not be labial to the incisal edge of the restoration.

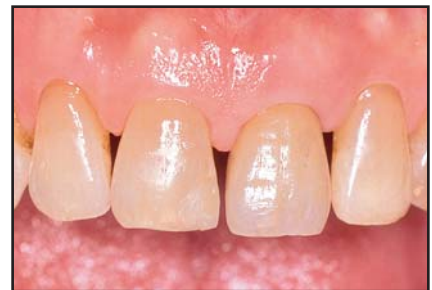

Fig 1d (right) Facial view of the definitive restoration.

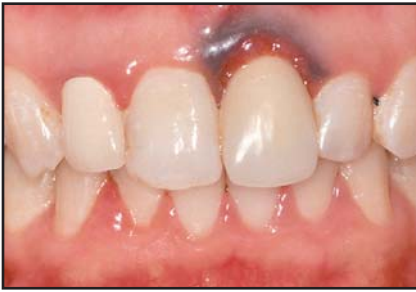

Fig 2a (left) This case is categorized as class 2. At the initial examination, an amalgam tattoo and root fracture were evident at the maxillary left central incisor.

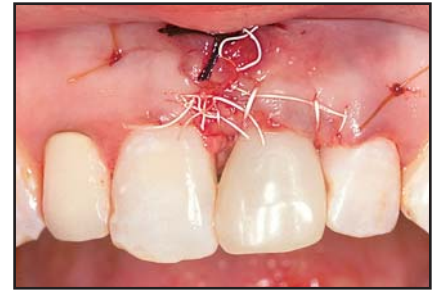


Fig 2b (right) The amalgam tattoo tissue was surgically excised, and a subepithelial connective tissue graft was placed.

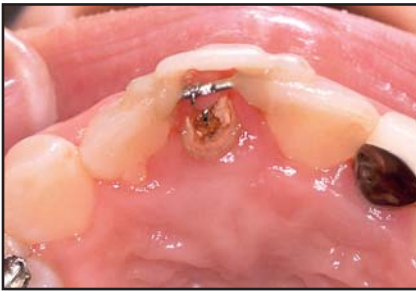

Fig 2c (left) Orthodontic eruption of the tooth intended for extraction was performed; following confirmation of the resulting bone level, both interproximally and labially, the tooth was extracted with the aid of a periosteal elevator.

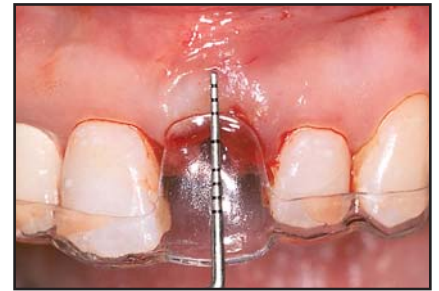

Fig 2d (right) Surgical guide in position prior to implant placement. The implant was placed, and an immediate provisional restoration, employed for both immediate esthetics and to provide optimal support for the soft tissues, was placed.

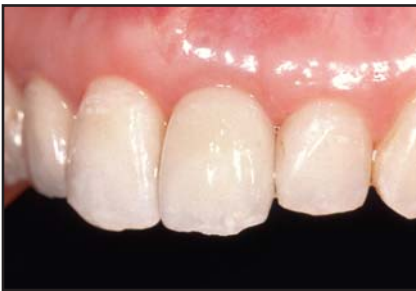

Fig 2e (left) Facial view of the definitive restoration on the maxillary left central incisor. A diminished or concave labial contour and positive interproximal support maintain the form of the free gingival margin and the height of the papillae.

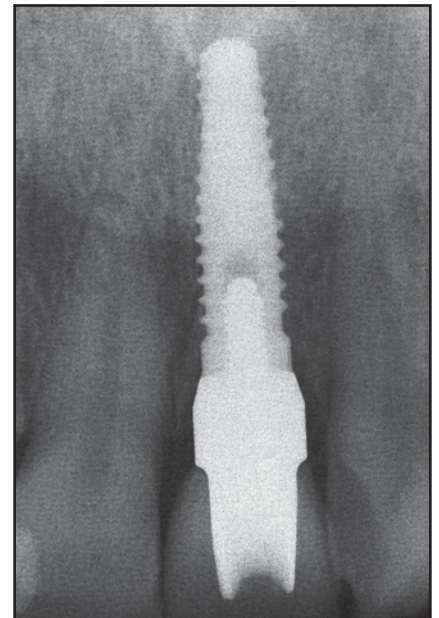


Fig 2f (right) Postoperative radiograph at 1 year.

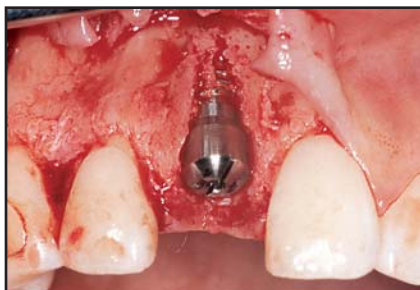

Fig 3a This case is categorized as class 3. Extraction with immediate implant placement was performed despite compromise to the buccal bone, but the implant was retained within the confines of the alveolar housing.

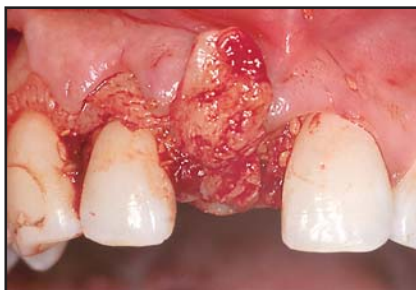

Fig 3b Connective tissue grafting in combination with GBR was used, incorporating a resorbable membrane. The connective tissue graft was used to optimize the esthetic soft tissue profile.

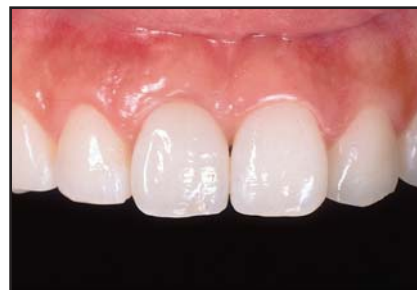

Fig 3c Facial view of the definitive restoration. While an "adequate" esthetic outcome was achieved, a small depression is evident in the buccal cervical region.

in thin biotypes, this method provides a more predictable and safer outcome (Fig 3).

- Class 4: The buccal bone is severely compromised, and implant placement within the remaining palatal bone results in a significantly off-axis implant position. In these cases, following extraction, implant placement should be delayed. If performed immediately, the long axis of the implant inclines toward the buccal and will result in a significant esthetic compromise of the definitive restoration. In these situations, the delayed approach should be used with subsequent 3D bone and soft tissue augmentation of the deficient ridge followed by optimal implant positioning.

In evaluating a potential site, care must be taken to ensure that the clinician's attempts to expedite implant placement within the available bone do not result in an implant that tends to extrude labially, thereby compromis-

ing the restorative esthetics. The long axis of the implant should be placed lingual to the incisor edge whenever possible to allow for both mechanical and surgical advantages in the definitive outcome. The lab will have more space to work with porcelain and to hide the prosthetic components, the restorative clinician will have more room to establish a proper emergence profile, and the surgeon will have less pressure placed onto the labial tissues.

Implant positioning, the resulting long axis, and soft tissue considerations

Vertical depth of implant head and direction of long axis

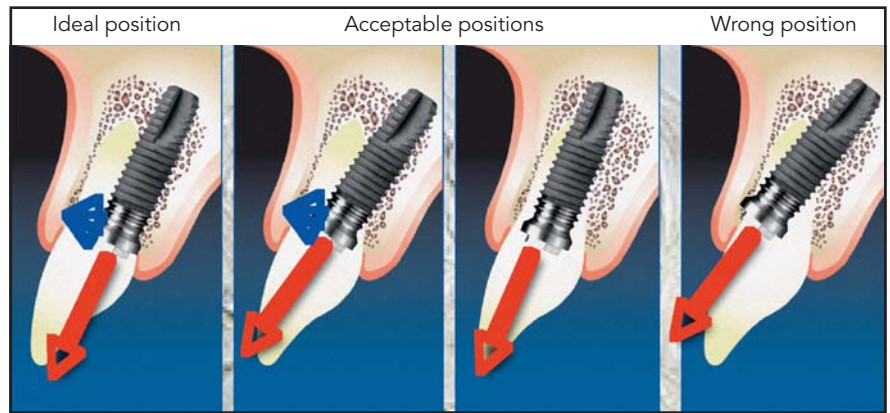
The platform of the implant should be located 2 to 4 mm below the midfacial aspect of the free gingival margin, with the extended long axis directed slightly lingual to the incisal edge of the definitive restoration (Fig 4). When the

long axis of the implant is inclined labially and projects beyond the incisal edge of the definitive restoration, the result is that the subgingival contours of the abutment or restoration will tend to deflect the gingival margin apically, resulting in an unharmonious esthetic profile.¹⁸ To correct this problem, the profile extending from the implant head to the free gingival margin requires a straight or negative angulation. Immediate placement generally cannot be performed in the wrong position without esthetic compromise.

Buccolingual position and labial region

Tarnow et al¹⁹ stated that a submerged implant, following abutment connection, will develop a vertical change in the osseous topography of 1.5 to 2 mm below the implant shoulder. In addition, circumferentially, or horizontally, this will create crater-shaped or horizontal/lateral bone resorption of 1.3 to 1.4 mm.¹⁶

Fig 4 Examples of the positions of immediately placed implants following orthodontic extrusion. These positions are classified based on both the osseous and soft tissue levels at the potential site at the time of extraction. Ideally, the implant engages the palatal wall of the extraction socket, and the extended long axis is directed slightly lingual to the incisal edge of the definitive restoration. Immediate placement generally cannot be performed in the wrong position without esthetic compromise.



Grunder et al²⁰ stated that at least 2 mm of lateral alveolar bone must be present beyond the body of the implant to compensate for the effects of bone remodeling. In the case of extraction with immediate implant placement, an implant should be placed lingually, avoiding the coronal 5 mm of labial bone and allowing for a gap of less than 2 mm, measured laterally from the periphery of the implant to the labial aspect of the socket. Grunder et al indicated that to support the gingival profiles, at least 2 mm of bone are necessary at the head of the implant measured laterally to allow for sufficient bone to remain in the esthetic position despite the naturally occurring horizontal cratering. Therefore, in any extraction with immediate implant placement, despite the necessity of maximizing the gap at 2.2 mm,²¹ it may be necessary to increase the size of this gap and actually refill it with a grafting material.^{7,22} This will ensure that, following horizontal bone remodeling, 1.5 mm of bone will still remain lateral to the buccal aspect

of the extraction socket following resorption to support the vertical height of the soft tissue. Implant designs that reportedly minimize crestal bone loss as a result of the abutment connection have recently been suggested.²³⁻²⁵ Elimination of abutment-to-implant micromovement, development of a hermetic bacterial seal, or the use of "platform switching" (smaller abutment with wider implant platform) could make esthetic implant treatment—particularly with adjacent implants—more esthetically predictable.^{24,25} However, the data on these potential solutions are still being evaluated.

Maynard and Wilson²⁶ related the risk of potential gingival recession to the gingival biotype and underlying alveolar bone. They indicated that a biotype with thin gingival tissue and thin alveolar bone has the highest risk of gingival recession.²⁶ Kan et al²⁷ reported that the thick gingival biotype has a more coronal level of gingival margin, with greater predictability than thin gingival biotype. It is

evident, then, that prior to implant placement, a thorough evaluation of the periodontal biotype is necessary; with the thin biotype, connective tissue grafting may be necessary to reduce soft and hard tissue compromise.

Mesiodistal position relative to the interdental zone

The head of an implant is positioned relative to the osseous on the direct labial; depending on the implant system used and particular philosophy, it is placed level or just coronal to it, or even slightly below the midcrestal bone. Of necessity and because of the flat head design of most implant systems, the interproximal aspect will extend well below the interproximal height of bone. This distance will vary with the periodontal biotype, ending up considerably deeper in the scalloped as opposed to the flat biotype. Salama et al¹² have developed a classification system for the predictable

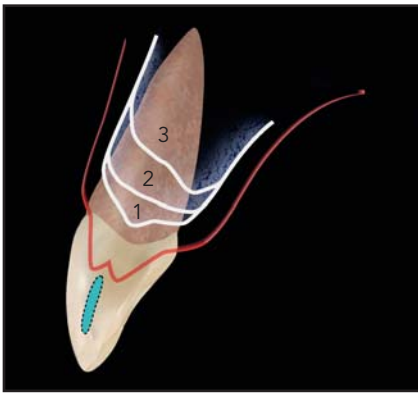


Fig 5a (left) Classification of interproximal bone height (IHB). 1 = Optimal result; IHB 2 mm from the cemento-enamel junction (CEJ) and 4 to 5 mm from contact point. 2 = Unfavorable result; IHB 4 mm from CEJ and 5 to 7 mm from contact point. 3 = Severe result; IHB > 5 mm from CEJ and > 7 mm from contact point.

Fig 5b (right) Apical extent of the contact point (A), IHB on the natural tooth (B), and IHB on the implant (C).

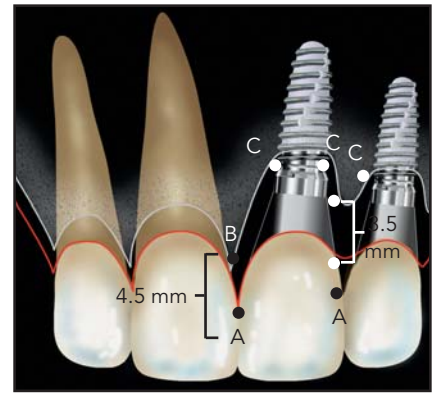


Table 2		Salama et al¹² classification of predicted height of interdental papillae	
Class	Restorative environment	Proximity limitations	Vertical soft tissue limitations
1	Tooth-tooth	1.0 mm	5.0 mm
2	Tooth-pontic	N/A	6.5 mm
3	Pontic-pontic	N/A	6.0 mm
4	Tooth-implant	1.5 mm	4.5 mm
5	Implant-pontic	N/A	5.5 mm
6	Implant-implant	3.0 mm	3.5 mm

height of the interdental papillae, as determined by the restorative elements on either side of the implant site (Table 2, Fig 5). The six classifications are differentiated by whether a papilla has a tooth, a pontic, or an implant on either side of it. Their data indicated that the vertical height from the tip of the interdental papilla between two implants was in excess of 2 mm less than that between an implant and a pontic; this resulted in a much shorter papilla and a longer restorative contact point.¹² This classification system and its associated treatment planning algorithm allow the clinician to prognostically plan for esthetic soft tissue contours by selecting the

most appropriate fixed restorative option based upon the available vertical bone support.

The numeric values just described may well be a result of the difference in the attachment modality of soft tissue in the natural tooth or pontic as opposed to the implant, in combination with the result of the remodeling of the peri-implant bone following abutment connection. The Salama et al¹² classification also described the horizontal dimension necessary between the restorative elements to facilitate the predictable presence of a papilla—for instance, the implant-to-implant dimension should, at a minimum, be 3 mm, whereas the necessary dimension

between an implant and a tooth can be considerably less, at only 1.5 mm.^{20,28} It is their contention that, with the present design of implants, the use of a pontic between implants improves the relative height of the papillae and the overall esthetic gingival outcome.^{23–25} Evolving changes in implant design, such as the single-body design or a two-piece implant system with a biologically “invisible” connection, may decrease the potential for crestal bone remodeling and resultant soft tissue changes. In addition, it appears from the work of Abrahamson et al²⁹ that every incident of abutment connection and disconnection enhances the process of bone remodeling.

The 4D concept in complex cases

In multiple-implant cases associated with bone defects (Fig 6), the use of strategically timed serial extractions is exceedingly important to support a fixed provisional restoration during ridge reconstruction and implant site development. Key abutments are selected at optimal positions to sup-

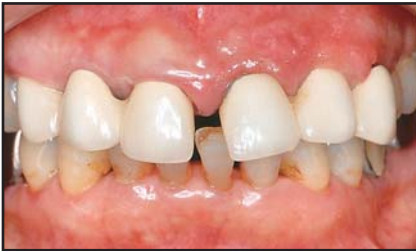

Fig 6a Case 4. Preoperative facial view. The maxillary anterior teeth show collapse of the supporting bone.

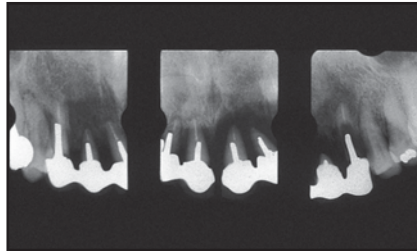


Fig 6b The left central and lateral incisors exhibit bone resorption beyond the apex.

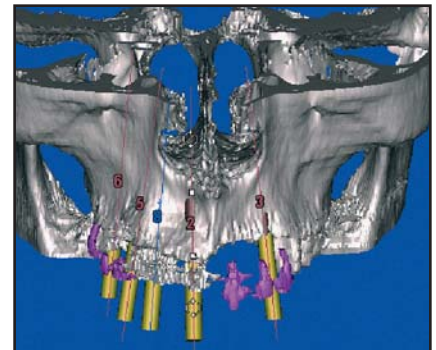


Fig 6c Three-dimensional image using computer simulation software exhibits the horizontal and vertical bone defects in the anterior region.

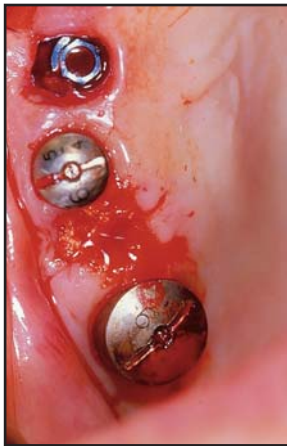

Fig 6d Implants were placed in the positions of the right first molar, right first premolar, right central incisor, and left canine with sinus augmentation and GBR. The right central incisor site was an immediate placement site categorized as a class 3. At the right canine site, which was categorized as class 1, extraction and immediate implant placement were postponed until the previously placed implants were integrated and placed into function in the provisional prosthesis. The implant was placed toward the palate to secure a full 2 mm of distance from the labial bone. It was determined that if the existing contour was maintained, the IHB presented a high potential to preserve the papilla between the implants.

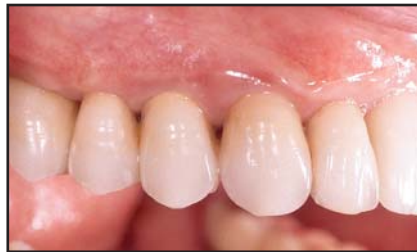

Fig 6e Lateral view of the right side after definitive cementation. In the canine area, implant placement allowed for the preservation of the tissue around the implant. This natural-looking outcome was achieved by using the 4D concept.

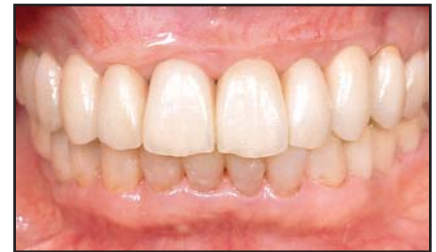

Fig 6f The definitive result. A moderately natural appearance was obtained and acceptable interdental papillae maintained.

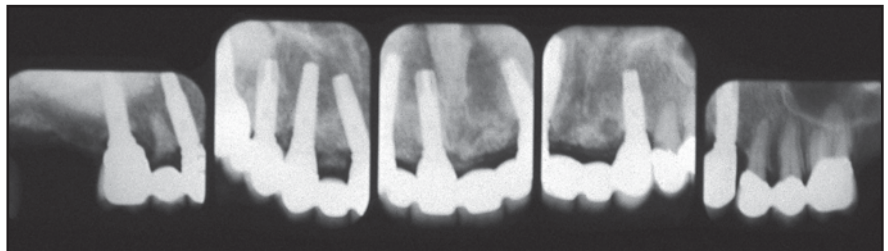


Fig 6g Postoperative periapical radiographs. The bone crest between the maxillary right canine and first premolar was maintained at a higher level than the horizontal platform of the implant. The appropriate interproximal height of bone was retained in the implant region.

port a splinted full-arch provisional restoration while the ineffectual teeth are extracted and hard and soft tissues are reconstructed; implants are then placed. Following osseointegration, these implants are in turn used to support a new provisional restoration or incorporated into the existing provisional.

The decision needs to be made on a tooth-by-tooth basis as to whether the remaining teeth that previously supported the provisional should be extracted and made into a pontic site with socket preservation techniques or sectioned below the crest of the ridge and below a connective tissue graft to preserve or redevelop the soft tissue esthetics. During implant placement, these key natural abutment teeth are used as guides to the vertical potential for augmented tissues as well as to the level of vertical placement of the implant. The pre-existing IHB on these remaining teeth is the limiting factor in the soft tissue potential for an esthetic restoration. Obviously these key abutments need to be relatively stable to support the restoration. These provisional abutment teeth demonstrate the key role of the fourth dimension of time in 4D implant therapy, as the relative timing of the extractions is obviously a key component in predictable implant treatment planning.

Conclusion

A correct understanding of the indications and classification for immediate implant placement will dramatically aid the clinician in determining an appropriate treatment plan and time frame for individual tooth extractions and implant placement in single implant cases as well as complex multiple implant cases. This expansion of the 3D "spatial" placement of implants into a 4D concept uses timing as a key variable in the development of esthetic implant restorations.

Acknowledgments

The authors would like to thank Dr Myron Nevins and Dr Yoshiro Ono for their encouragement and support.

References

1. Garber DA, Belser UC. Restoration driven implant placement with restoration-generated site development. *Compend Contin Educ Dent* 1995;16:796–804.
2. Garber DA. The esthetic dental implant: Letting restoration be the guide. *J Am Dent Assoc* 1995;126:319–323.
3. Carlsson GE, Thilander H, Hedegard B. Histologic changes in the upper alveolar process after extractions with or without insertion of an immediate full denture. *Acta Odontol Scand* 1967;25:21–43.
4. Schropp L, Wenzel A, Kostopoulos L, Karning T. Bone healing and soft tissue contour changes following single-tooth extraction: A clinical and radiographic 12-month prospective study. *Int J Periodontics Restorative Dent* 2003;23:313–323.
5. Nevins M, Camero M, Friedland B, et al. A study of the fate of the buccal wall of extraction sockets of teeth with prominent roots. *Int J Periodontics Restorative Dent* 2006;26:19–29.
6. Lazzara RJ. Immediate implant placement into extraction sites: Surgical and restorative advantages. *Int J Periodontics Restorative Dent* 1989;9:332–343.
7. Wilson TG, Schenk R, Buser D, Cochran D. Implants placed in immediate extraction sites: A report of histologic and histometric analyses of human biopsies. *Int J Oral Maxillofac Implants* 1998;13:333–341.
8. Paolantonio M, Dolci M, Scarano A, et al. Immediate implantation in fresh extraction sockets. A controlled clinical and histological study in man. *J Periodontol* 2001;72:1560–1571.
9. Chen ST, Wilson TG Jr, Hammerle CH. Immediate or early placement of implants following tooth extraction: Review of biologic basis, clinical procedures, and outcomes. *Int J Oral Maxillofac Implants* 2004;19(suppl):12–25.
10. Chen ST, Darby IB, Adams GG, Reynolds EC. A prospective clinical study of bone augmentation techniques at immediate implants. *Clin Oral Implants Res* 2005;16:176–184.
11. Covani U, Barone A, Cornellini R, Crespi R. Soft tissue healing around implants placed immediately after tooth extraction without incision: A clinical report. *Int J Oral Maxillofac Implants* 2004 Jul–Aug;19:549–553.
12. Salama H, Salama MA, Garber D, Adar P. The interproximal height of bone: A guidepost to predictable aesthetic strategies and soft tissue contours in anterior tooth replacement. *Pract Periodontics Aesthet Dent* 1998;10:1131–1141.
13. Grunder U. Stability of the mucosal topography around single-tooth implants and adjacent teeth: 1-year results. *Int J Periodontics Restorative Dent* 2000;20:11–17.

14. Cochran DL, Hermann JS, Schenk RK, Higginbottom FL, Buser D. Biologic width around titanium implants. A histometric analysis of the implanto-gingival junction around unloaded and loaded nonsubmerged implants in the canine mandible. *J Periodontol* 1997;68:186–198.
15. Berglundh T, Lindhe J. Dimension of the peri-implant mucosa. Biological width revisited. *Clin Periodontol* 1996;23:971–973.
16. Small PN, Tarnow DP. Gingival recession around implants: A 1-year longitudinal prospective study. *Int J Oral Maxillofac Implants* 2000;15:527–532.
17. Salama H, Salama M. The role of orthodontic extrusive remodeling in the enhancement of soft and hard tissue profiles prior to implant placement: A systematic approach to the management of extraction site defects. *Int J Periodontics Restorative Dent* 1993;13:312–333.
18. Saadoun AP, Le Gall M. Selection and ideal three-dimensional implant position in the anterior aesthetic zone. *Int Mag Oral Implantol* 2003;4(4):8–18.
19. Tarnow DP, Cho SC, Wallace SS. The effect of inter-implant distance on the height of inter-implant bone crest. *J Periodontol* 2000;71:546–549.
20. Grunder U, Gracis S, Capelli M. Influence of 3-D bone-to-implant relationship on esthetics. *Int J Periodontics Restorative Dent* 2005;25:113–119.
21. Botticelli D, Berglundh T, Lindhe J. Resolution of bone defects of varying dimension and configuration in the marginal portion of the peri-implant bone. An experimental study in the dog. *J Clin Periodontol* 2004; 31:309–317.
22. Saadoun AP, LeGall M, Toutai B. Current trends in implantology: Part II—Treatment planning, aesthetic consideration, and tissue regeneration. *Pract Proced Aesthet Dent* 2004;16:707–714.
23. Wohrle PS. Nobel Perfect esthetic scalloped implant: Rationale for a new design. *Clin Implant Dent Relat Res* 2003;5(suppl 1):64–73.
24. Lazzara RJ, Porter SS. Platform switching: A new concept in implant dentistry for controlling postrestorative crestal bone levels. *Int J Periodontics Restorative Dent* 2006;26:9–17.
25. Baumgarten H, Cacchetto R, Testori T, Meltzer A, Porter S. A new implant design for crestal bone preservation: Initial observations and case report. *Pract Proced Aesthet Dent* 2005;17:735–740.
26. Maynard JG Jr, Wilson RD. Physiologic dimensions of the periodontium significant to the restorative dentist. *J Periodontol* 1979;50:170–174.
27. Kan JYK, Rungcharassaeng K, Umezu K, Kois J. Dimensions of peri-implant mucosa: An evaluation of maxillary anterior single implants in humans. *J Periodontol* 2003; 74:557–562.
28. Tarnow DP, Cho SC, Wallace SS. The effect of inter-implant distance on the height of inter-implant bone crest. *J Periodontol* 2000;71:546–549.
29. Abrahamson I, Lindhe J. The mucosal barrier following abutment dis/reconnection. An experimental study in dogs. *J Clin Periodontol* 1997;24:568–572.